

Bonopty®

Transsternal core biopsies

Case history

Known renal carcinoma. New retro-sternal lesion (lesion in the anterior mediastinum).

Biopsy details

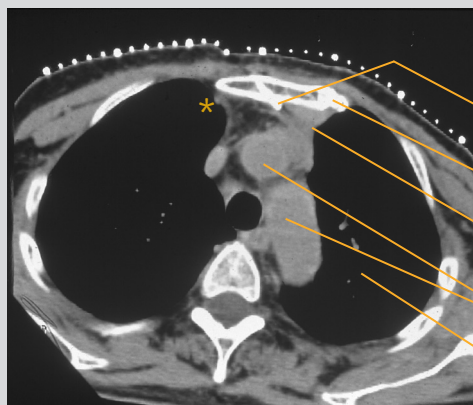
Bonopty® Extended Drill was used for a controlled, length-matched sternal penetration. This was then exchanged for Bonopty® Biopsy Cannula (of the same length). Core biopsies were obtained with an automatic cutting needle through Bonopty® Biopsy Cannula.

Analysis of the samples

Metastasis was diagnosed.

Comments

Bonopty® Biopsy System was tilted to ensure a safe throw, avoiding the aortic arch and pleura (lungs). This approach could be an alternative to mediastinoscopy on lesions not accessible using a parasternal percutaneous approach. The latter presents a greater risk of injuring the internal mammary vessels* or of pneumothorax.



CT scan of the thorax

Tilted Bonopty® Biopsy Cannula

Sternum

Lesion

Aortic arch

Thoracic cavity

Courtesy of Dr K. Gunnar O. Åström and Dr K. Håkan Ahlström, Uppsala University Hospital.

Reference:

Hagberg Hans, Ahlström K Håkan, Magnusson Anders, Sundström Christer, Åström K. Gunnar O.: Value of Transsternal Core Biopsy in Patients with a Newly Diagnosed Mediastinal Mass: Acta Oncologica 2000; 39, No.2: 195-198.

Bonopty® is a registered trademark of AprioMed AB, Sweden.

Acknowledgements: