

Bonopty®

Penetration of a thin sclerotic pedicle

Case history

Sclerotic vertebrae in patient without known malignancy.

Biopsy details

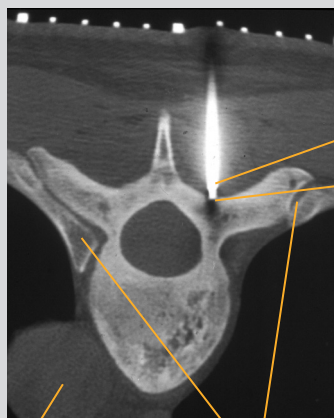
Bonopty® Extended Drill was advanced through a sclerotic area in the thin pedicle. The extended drill was then exchanged for the Bonopty® Biopsy Cannula and a deeper sample from the vertebral body was collected.

Analysis of the samples

The acquired samples were highly adequate for analysis and showed no malignancy.

Comments

The drill tip and penetration cannula were anchored with only minor axial force (finger-tip pressure), which allows finer control and therefore less risk of slipping and hitting susceptible structures. In this case the extended drill was necessary to use as the biopsy cannula could not penetrate the thin sclerotic pedicle.



Aorta

Ribs

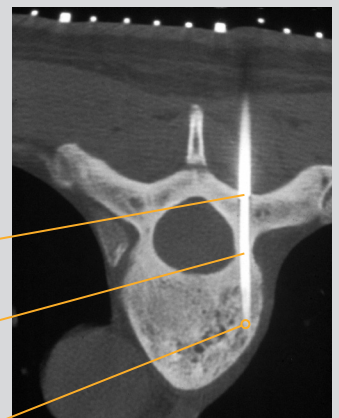
CT scans of the fifth thoracic vertebra, transpedicular approach

Bonopty® Penetration Cannula and Drill

Bonopty® Penetration Cannula now anchored in the cortex.

Bonopty® Extended Drill was used to pass the thin sclerotic pedicle.

Sample acquired here with Bonopty® Biopsy Cannula



Acknowledgements:
Courtesy of Dr K. Gunnar O. Åström and Dr K. Håkan Ahlström, Uppsala University Hospital.

Bonopty® is a registered trademark of AprioMed AB, Sweden.