

Bonopty®

Multiple sampling/passing a sclerotic lesion

Case history

Patient with a sclerotic lesion in the pelvis.

Biopsy details

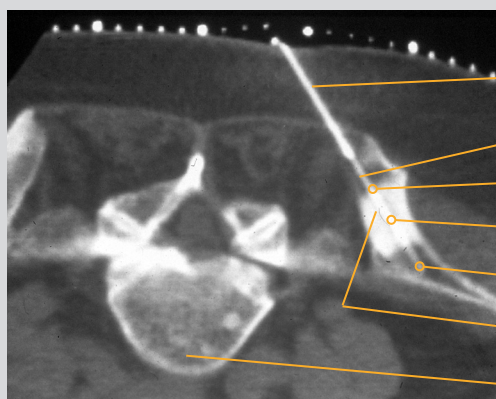
Three samples were obtained with Bonopty® Biopsy Cannula, each progressively deeper as the sclerotic lesion was penetrated (third sample from beyond the sclerotic area).

Analysis of the samples

The lesion was diagnosed as a carcinoid metastasis.

Comments

Multiple biopsies were easily performed through the anchored Bonopty® Penetration Cannula. It was possible to pass and repeatedly sample this sclerotic lesion with Bonopty® Biopsy Cannula. The outer reduction of the Bonopty® Biopsy Cannula facilitates passage of the cannula through sclerotic lesions.



CT scan of the pelvis (posterior iliac crest)

Bonopty® Penetration Cannula

Bonopty® Biopsy Cannula

1st sample

2nd sample

3rd sample

Sclerotic lesion

5th Lumbar vertebra

Acknowledgements:

Courtesy of Dr K. Gunnar O. Åström and Dr K. Håkan Ahlström, Uppsala University Hospital.

Bonopty® is a registered trademark of AprioMed AB, Sweden.