

SeeStar®

Support during superficial puncture

Case History

46 year old male with a mass in his lateral gastrocnemius. Initial diagnosis appeared to be hemangioma or a ganglion cyst.

Biopsy Details

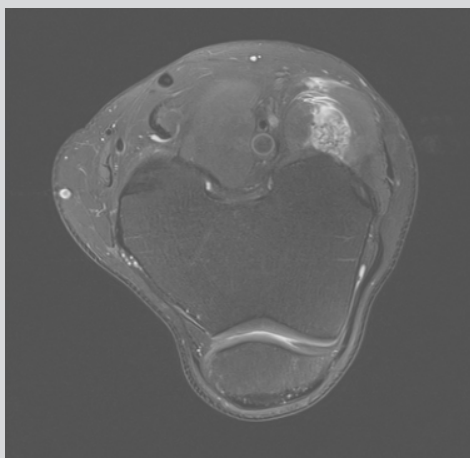
The lesion was less than 2 cm beneath the skin. SeeStar® (17G pink) anchored the coaxial 19G 6 cm needle. Several 20G core passes were made along with 22G FNA's.

Analysis of the Samples

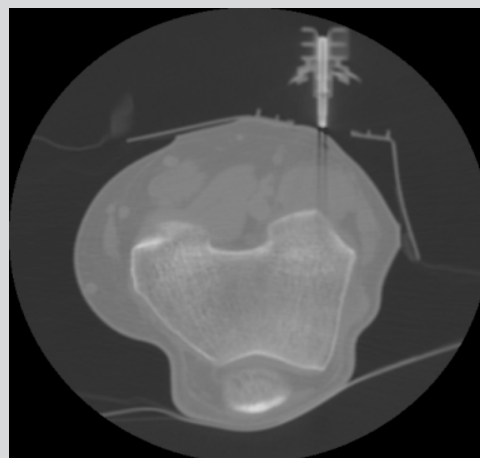The pathology proved a ganglion cyst.

Comments

The orthopedic oncologist prefers to biopsy most lesions with CT instead of ultrasound so he can visualize the needle track easier. Since the lesion was less than 2 cm beneath the skin, SeeStar® anchored the coaxial 19G 6 cm introducer needle.



Pre-procedure MRI



SeeStar® Localization

Acknowledgement:
Courtesy of Eric Callaghan, MD Marshfield Clinic, Marshfield WI, USA

SeeStar® is a registered trademark of AprioMed AB, Sweden.